

# A REVIEW OF DEBRISOFT IN THE MANAGEMENT OF A VARIETY OF DERMATOLOGICAL CONDITIONS

Debbie Lorenzelli, Alberto Barea, Clare Morris

This product review examines Debrisoft utilising Monofilament Fibre Technology. Debrisoft is known for its ability to remove dry skin and for the removal debris and barriers to healing from acute and chronic wounds during a process known as wound bed preparation. Debrisoft has recently had its clinical indication extended to include dermatological conditions such as eczema and psoriasis.

Lorenzelli D, Barea A, Morris C. A review of Debrisoft in the management of a variety of dermatological conditions. *Dermatological Nursing* 2018. 17(2): 33-38

Skin problems represent a big slice of NHS activity. Indeed, in 2006, it was reported that in England and Wales around 24% of the population (12.9 million) seek medical advice about a skin condition each year, with the most common reasons being skin infection and eczema.<sup>1</sup>

In the UK, it is estimated that 70% of older people have a skin condition and eczema is one of the most common conditions.<sup>2</sup> In more recent publications<sup>3</sup> it has been suggested that 23-33% of the population have a skin problem, and in surveys<sup>3</sup> around 54% of the UK population experience a skin condition in a given twelve month period.

Skin conditions cause physical discomfort, psychological distress and generally are long-term chronic conditions. Skin diseases remain a major cause of disability worldwide.<sup>4</sup>

Debbie Lorenzelli is a Dermatology Nurse Specialist at St Helens and Knowsley Teaching Hospital NHS Trust. Alberto Barea is Lead Clinical Nurse Specialist at Plastic Surgery and Dermatology, Kingston Hospital NHS Foundation Trust. Clare Morris is Senior Clinical Services Manager, L&R Medical UK Ltd.

## Product focus – Debrisoft

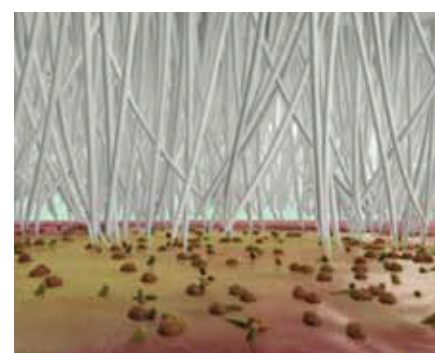
Debrisoft utilises Monofilament Fibre Technology (Figure 1) in the form of a debridement pad and debridement device or lolly. The pad comprises of 18 million special monofilament fibres that have angled tips to reach uneven areas



**Figure 1.**  
Monofilament Fibre Technology™

of the skin or wound bed (Figure 2) and will not damage new granulating tissue or epithelial cells.

Debrisoft has a unique technology and mode of action for wounds and skin, lifting debris, including biofilm,



**Figure 2.**  
18 million special monofilament fibres which have angled tips to reach uneven areas of the skin or wound bed™

superficial slough and exudate quickly, binding it within the fibres (Figure 2) and removing barriers to healing.

It is soft and conformable and gentle on patients. It is also safe and easy to use and can also be used by patients for self-care.

After examining clinical evidence, NICE concluded: "The likely benefits of using the Debrisoft pad on appropriate wounds are that they will be fully debrided more quickly, with fewer nurse visits needed, compared with other debridement methods. In addition, the Debrisoft pad is convenient and easy to use, and is well tolerated by patients".<sup>5</sup>

Following the products launch in 2011, it quickly became established for use in acute and chronic wound care,<sup>6</sup> and in the management of skin conditions associated with chronic venous disease<sup>7</sup> and lymphedema.<sup>8</sup> In recent years, Debrisoft has also been used more in the field of dermatology.

How to use Debrisoft

## Debrisoft®



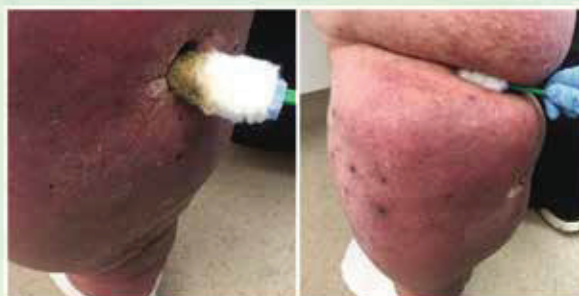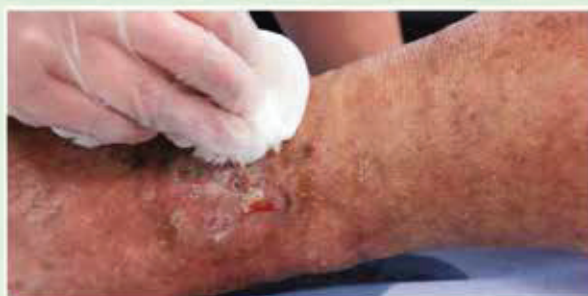For shallow wounds and accessible areas of skin

## Debrisoft® Lolly



For hard-to-reach areas e.g. cavity wounds, between digits and skin folds

Debrisoft® and Debrisoft® Lolly may be used in combination



### How to use Debrisoft®



**Step 1.** Fully moisten the soft, fleecy side of Debrisoft® with 20–40ml (1–2 egg cups) of tap water or saline.†



**Step 2.** With gentle pressure, use the soft, fleecy side of the moistened Debrisoft® in a circular motion (on wounds) or in long, sweeping strokes (on the skin).



**Step 3.** Typically, a new Debrisoft®/Debrisoft® Lolly is used for each separate wound/area of skin.†

### How to use Debrisoft® Lolly



**Step 1.** Fully moisten the head of the Debrisoft® Lolly with 5–15ml (1–3 teaspoons) of tap water or saline.†



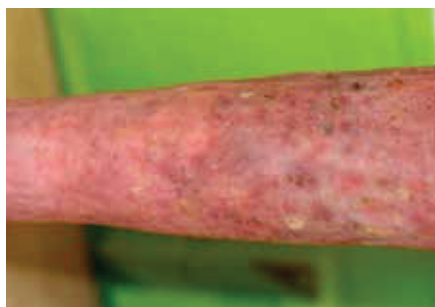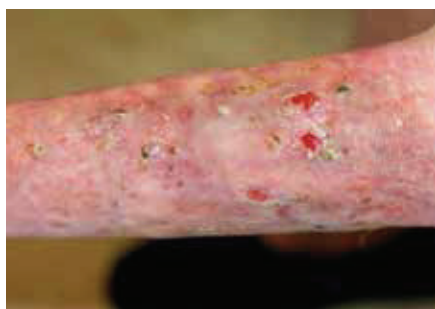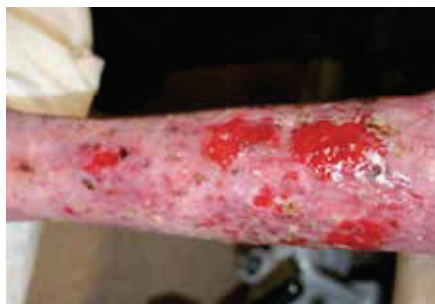**Step 2.** With gentle pressure, use the moistened head of the Debrisoft® Lolly, using forward/backward/rotational movements.

†Always refer to local guidelines. Debrisoft® and Debrisoft® Lolly are single-use. Dispose of in normal clinical or household waste.

### Review of the dermatology related evidence

Flinton<sup>7</sup> describes the use of Debrisoft in varicose eczema following 3 years of unsuccessful management associated with high costs. Five Debrisoft treatments over a two week period resulted in the wounds and varicose eczema healing at the end of the two week period (Figures 3-5). Debrisoft was continued to prevent the build-up of hyperkeratosis.

Denyer<sup>9</sup> reports on the use of Debrisoft in the management of children with severe epidermolysis bullosa. This condition is extremely challenging, with wound management often being painful and time consuming. Denyer recommends that Debrisoft is introduced from infancy as it can be difficult to introduce new products later in life. Denyer states that Debrisoft will hopefully help in early detection of squamous cell carcinoma, as these tumours are often concealed beneath crusts and debris.



Figures 3,4 and 5.

Weindorf and Dissemond<sup>10</sup> discuss the challenges of debridement of painful chronic wounds in dermatological patients such as pyoderma gangrenosum and epidermolysis bullosa. Debrisoft proved to be a useful, non-invasive and therefore safe alternative, especially for chronic wounds covered in fibrin and slough.

Girip and McLoughlin<sup>11</sup> report in a case study the management of a lady with a three year history of venous leg ulcer, recurrent cellulitis and chronic eczema that was successfully managed with debridement of the wound and skin with Debrisoft in her own home. It was important for this patient that a hospital admission was prevented, not only to prevent the distress a hospital admission would have caused her, but to prevent the costs associated with admission.

An interim report<sup>12</sup> described the use of Debrisoft in the management of psoriasis and dry, scaly skin on two healthy volunteers. The basis of the study was to examine if it is possible to use Debrisoft in the management of skin conditions such as psoriasis and dry, scaly skin without adverse effect on the skin, and to establish whether there was sufficient basis for a more extensive study.

Two volunteer subjects participated in this short study. Measurements were made using different measurement techniques including the Tissue Viability Imager; Visioscan, Corneometer; Tewameter; Mexameter; Colorimeter and Skin Thermometer. Following baseline measurements Debrisoft was moistened and applied using a wiping motion to affected areas of skin. Twenty minutes after treatment a further set of measurements were made.

In most cases the erythema measurements were increased, which may indicate an increased blood flow to the area. This is most likely due to the massaging effect of Debrisoft. The hydration figures were mostly increased. If the Debrisoft was causing damage to the skin the hydration figures would be decreased. Initial TEWL results would indicate that the monofilament pad does not impair the barrier function of the skin.

The authors concluded that whilst acknowledging limitations of the study, they believed that the evidence indicates that the use of Debrisoft on psoriasis or dry, scaly skin would not cause harm and may, in longer term testing, show benefits.

A multicenter case series evaluating Debrisoft in the management of childhood atopic eczema and psoriasis was undertaken.<sup>13</sup>

The primary aim of this clinical evaluation was to investigate if Debrisoft would benefit the skin care regime of children suffering from atopic eczema and psoriasis compared with their current regime and if that benefit led to preservation of the epidermal barrier by improving penetration of creams and emollients.

The intervention was offered to the parents and was compared with their current regime of gauze, flannel and sponge.

Key results with Debrisoft were that in all 33 cases the condition was not made worse and in 31/33 cases no pain or discomfort was experienced. This was compared with 23/33 cases with their previous regime causing pain and 22/33 cases where the condition was made worse due to increased itching and bleeding. In 31/33 cases dry skin came away more easily with the Debrisoft than with standard practice. There were many positive comments received from parents, children and clinicians during the study.

**Key results with Debrisoft were that in all 33 cases the condition was not made worse and in 31/33 cases no pain or discomfort was experienced**

In all parameters Debrisoft led to an improved skin care regime when compared to their usual practice. Parents found it easier to apply creams and emollients, and the affected area felt smoother. It was pain and trauma free, and they would continue to use the product as part of the daily management of their child's skin condition.

In 2014, the first national guidance document was produced,<sup>14</sup> outlining the management of hyperkeratosis of the lower limb. This was followed in 2015 by a UK consensus document.<sup>15</sup> Both documents acknowledge the role of Debrisoft in the management of lower limb hyperkeratosis and how it can be used by all health care professionals working in hospital or community and by patients and carers. Its ease of use may encourage patients to take an active role in their care and undertake exfoliation of their own hyperkeratosis and dry skin.<sup>15</sup>

It is very important that hyperkeratosis is removed in a safe, atraumatic, way as any disruption of the skin integrity, for example by using forceps, increases the risk of cellulitis.<sup>16</sup> Removing the dry scaly skin also allows emollients to penetrate, and so rehydrates the skin.<sup>16</sup> Whitaker describes a case study of a female patient who had previously experienced leg ulcers and was managed in ill-fitting compression hosiery giving less than therapeutic compression levels. An accumulation of emollients, coupled with the ill-fitting hosiery and hyperkeratosis had led to cellulitis.<sup>16</sup> Debrisoft was used over a two-week period along with new compression hosiery and light emollient therapy.

Pidcock and Jones report on a case study that illustrates the importance of the removal of hyperkeratosis with Debrisoft to facilitate effective compression therapy.<sup>17</sup> In cases of chronic oedema, hyperkeratosis needs to be reduced as this leads to a softening of the skin and tissues. When the skin and tissues are softer you can achieve reduction in limb volumes.<sup>18</sup>

Johnson et al<sup>19</sup> describe a multi-centre observational study examining the effects of Debrisoft in chronic wounds and hyperkeratosis. During the evaluation, Debrisoft was found to be very easy to use and easily transferable into practice; not only does it look simple but it actually is simple to use in hospitals and community settings requiring very little educational input or training for use.

Several secondary skin changes develop as a result of chronic oedema and lymphoedema such as thickening of the skin, skin folds and papillomatosis. The

mainstay of treatment in these situations are based on four main components; skin care, exercise, lymphatic drainage and external compression and support. Greaves<sup>20</sup> and Harding<sup>21</sup> both report on the devastating psychological and social impact of these conditions and how the management of the skin changes with Debrisoft along with management of the other mainstay components led to considerable improvements in quality of life, organisational cost savings.

Whiteside and McIntyre<sup>22</sup> describe how they utilised the role of the band 3 health care assistant in providing skin care for lymphoedema patients in a clinic setting under the direction of the lymphoedema specialist. They utilised Debrisoft to manage and prevent hyperkeratosis keeping the skin in good condition and allowing emollients to penetrate the skin, preventing cracks appearing and preventing cellulitis.

Elwell<sup>23</sup> explains that until recently there was no clear consensus for the management of hyperkeratosis. This has led to time consuming practice that is sub-optimal, often ineffective and time consuming for patients and services. She describes the impact of the publication of the consensus recommendations<sup>15</sup> and how it led to service improvements and patient satisfaction.

Freeman et al<sup>24</sup> outlines how important it is to ensure the barrier function of the skin is maintained in patients with lymphoedema. As such, good skin care is one of the cornerstones of treatment; for example, the removal of hyperkeratosis and meticulous cleaning of papillomatosis, including cleaning between skin folds and toes. She describes how she uses Debrisoft Lolly on these types of patients and examines the care of one particular patient with excellent results.

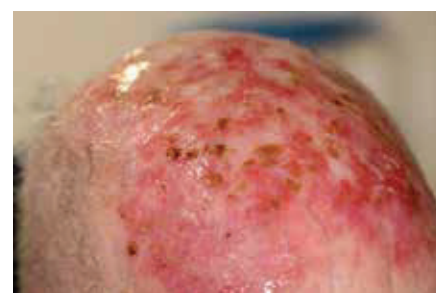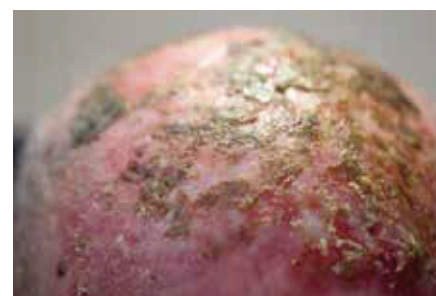Skin problems can exist in diabetic patients and within diabetic foot management, debridement of callus tissue is a general but important component in both prevention and management of ulceration. A document was written and developed by Foot in Diabetes UK, and provides a framework outlining the competencies and skills to practice with

confidence.<sup>25</sup> Debrisoft is outlined as a wound and skin debridement technique which requires minimal training and being convenient and easy to use in patient's home, GP surgery or an inpatient setting.<sup>5</sup>

### Debrisoft is outlined as a wound and skin debridement technique which requires minimal training

Young<sup>26</sup> describes the introduction of a skin care regimen in an elderly inpatient population. The elderly often suffer from dry skin when in hospital due to the aging process, frequent cleansing and the temperature and lack of humidity in the hospital environment. Young used Debrisoft which facilitated the skin being in the optimal condition to benefit from the subsequent application of the emollient therapy. This led to anecdotally fewer incidences of skin tears to limbs potentially to improved integrity of the skin.

Actinic Keratosis (AK) are red or brown flat, scaly lesions that are rough to the touch.<sup>27</sup> Heron<sup>28</sup> describes the care of a patient aged 73 years who presented with a history of AK on his scalp which was extremely sensitive and at risk, due to a history of a squamous cell carcinoma excised from the area and then grafted. He was successfully managed with

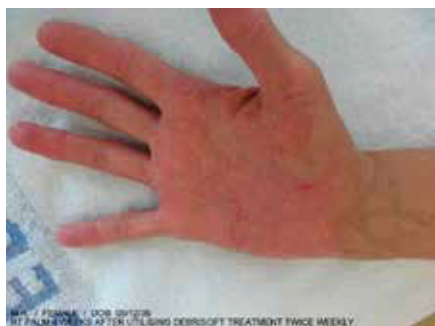
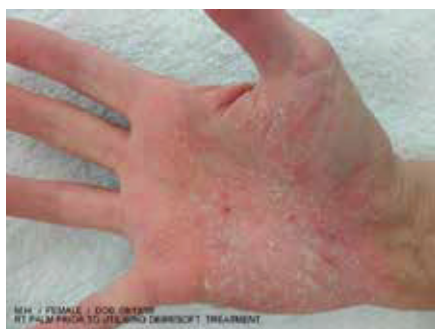
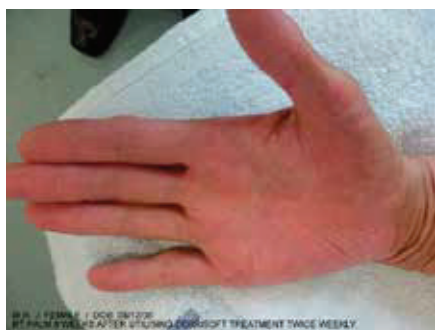Figures 6 and 7.

Debrisoft (Figures 6 and 7) following a holistic review leading to pain free, safe and effective treatment regime improving concordance and quality of life and reduced treatment costs and specialist hospital intervention.

The mother of a young male patient who suffers from hyperkeratosis as part of his epidermolytic ichthyosis used Debrisoft as part of his skin management.<sup>29</sup> She was impressed with the softness and, most importantly, he tolerated her wiping his skin with the Debrisoft. She commented that he had never tolerated any sort of cloth or towel, or anything rubbing his skin while washing.

Lorenzelli<sup>30</sup> undertook an evaluation in a nurse led hand and foot PUVA dermatology clinic using Debrisoft in the management of eight patients with hyperkeratotic psoriasis, hyperkeratotic eczema, palmar plantar pustulosis and



**Figures 8,9 and 10.**

psoriasis-form eczema of the hands and feet to determine if it would be more cost effective and patient friendly than standard local protocol. Patients were monitored for an eight-week period and reviewed at weeks 1, 4 and 8. A data collection form was used to document the findings with photography and DLQ Index.<sup>31</sup> This initial evaluation has its limitations due to the number of patients involved but gave the author the confidence to continue using the Debrisoft pad in the future.

This study had an enormously positive impact to the patients who suffer from these chronic, debilitating skin conditions of the hands and feet in terms of comfort, occupation and employment and their overall ability to self-manage their condition (Figures 8-10). One patient stated "I can now do what I couldn't do before".

The use of Debrisoft has been shown in this small service evaluation to potentially reduce the costs of treatment by reducing the clinical input of a band 7 specialist nurse in an acute hospital setting and reducing the number of treatments required to manage the conditions.

Edwards<sup>32</sup> describes the management of three patients with psoriatic arthritis and burn scars. Management of hypertrophic burn scar hyperkeratosis is extremely difficult and can be psychologically very distressing for patients as they do not feel they are making any progress, and therapeutic treatments often have to be stopped to allow wounds to re-heal. Given the psychological impact of a burn, even minor setbacks can often be viewed as catastrophic, so any adjunct that can help prevent this can have a significant impact.

In terms of the patient with psoriatic arthritis, there was resistance during her inpatient care to undertake use of Debrisoft at every dressing change, but once they could see an improvement in the wound, increased range of movement and decrease in pain they became much more involved with the treatment.

Photodynamic Therapy (PDT) is a recognised, well-established treatment. Preparation of the area to be treated is

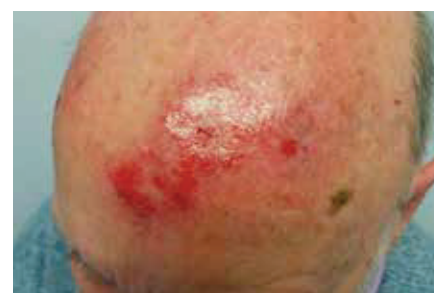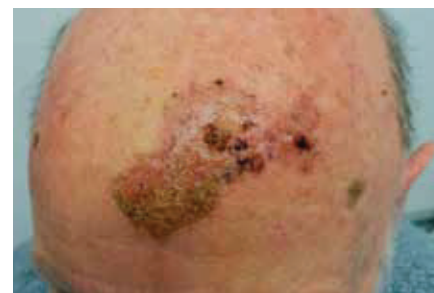paramount to achieving optimal results and can be achieved by removing the surface crust of scale by gently removing using gentle curettage or abrasion with a scalpel.

Barea<sup>33</sup> identified a scope for using Debrisoft during lesion preparation prior to PDT, with particular interest in:

- ▶▶ Potential reduction of time for debridement, and
- ▶▶ Improved patient's experience

In the 20 cases of PDT sessions, Debrisoft provided:

- ▶▶ 100% lesion debridement in 17 out of 20 episodes (Figures 11 and 12)
- ▶▶ Between 75% to 100% debridement in 3 episodes in lesions with firm scaling
- ▶▶ Shortest time for debridement with the monofilament fibre debridement pad was 10 seconds
- ▶▶ Longest time for debridement with the monofilament fibre debridement pad was 3 minutes and 23 seconds
- ▶▶ Average time spent for debridement was 69 seconds
- ▶▶ Average pain score was 2.5. A pain scale of zero to 10 had been used for each session allowing for the total number of pain points recorded for each regimen to be calculated. The total was then divided by the number of sessions for each individual, allowing a pain score ratio to be formulated.



**Figures 11 and 12.**

Barea concluded that Debrisoft can be used in conjunction with PDT by offering a quick and easy, manageable debridement, allowing potentially extra treatment time for sessions with other patients.

Acne Vulgaris is a common problem in youth and early adolescence and is characterised by areas of skin with increased oil-sebum secretion (seborrhoea) and the formation of comedones (blackheads and whiteheads), papules, as well as nodules. Scarring is often the result of the inflammatory processes within the dermis. There are many pharmacological and non-pharmacological therapies to remove the sebaceous clogging. Reduction of microbial burden is one such therapeutic option. Recent evidence is emerging that Debrisoft can have a role to play in the removal of excessive sebum and microbial burden.

Wiegand<sup>34</sup> was able to demonstrate the efficiency in cleaning by using a debridement model with artificial sebum. This led to Eberlein et al<sup>35</sup> undertaking a semi-systematic case series in seven young people suffering from retentive manifestation of acne vulgaris to collect practical findings of Debrisoft in combination with typical doses of polyhexanide and sodium-hypochlorite based solutions. The overall results of this first clinical experience were very encouraging and the user satisfaction was very positive.

## Scarring is often the result of the inflammatory processes within the dermis

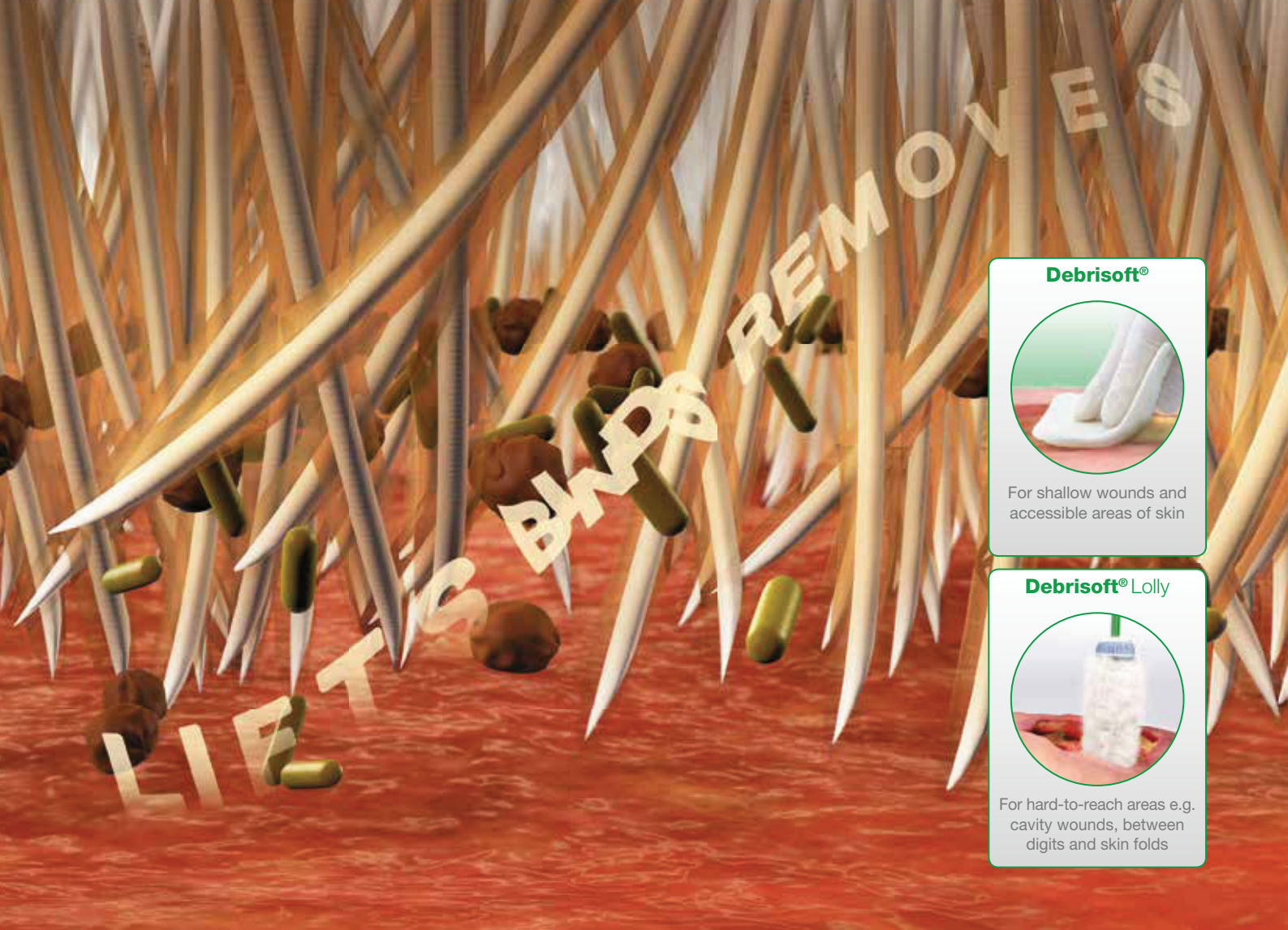
### Conclusion

This review of the dermatology related evidence to date using Debrisoft shows great promise for the treatment of a number of dermatological skin conditions as well as the management of acute and chronic wounds such as leg ulcers. It is acknowledged that the studies comprise of small case series and case studies and it would be beneficial to extend this to much larger studies with greater patient numbers. **DN**

### References

- RCGP weekly returns service annual report 2006
- Van Onselen J. Eczema and older people: introducing the Talking Eczema tool. *British Journal of Community Nursing* 2017. 22(2):62
- Skin conditions in the UK: a health care needs assessment (2009) Centre of Evidence Based Dermatology, University of Nottingham, UK
- Karimkhani C et al. Global skin disease morbidity and mortality: an update from the global burden of disease study 2013. *JAMA Dermatology* 2017. 153(5):406-412
- National Institute for Health and Care Excellence (NICE) (2014). The Debrisoft monofilament debridement pad for use in acute or chronic wounds. London: NICE. Available at: [guidance.nice.org.uk/mtg17](http://guidance.nice.org.uk/mtg17) [Last accessed May 2018]
- Bahr S et al. Clinical efficacy of a new monofilament fibre containing wound debridement product. *Journal of Wound Care* 2011. 20(5)
- Flinton R. A new solution to an old problem – an innovative active debridement system. Poster presentation, Wounds UK conference, Harrogate, UK 2011
- Management of hyperkeratosis of the lower limb: consensus recommendations. London: *Wounds UK* 2015. 11(4). Supplement
- Denyer J. The use of debridement pads in the management of children with severe Epidermolysis Bullosa. Poster presentation. EWMA conference, Copenhagen, Denmark 2013
- Weindorf M, Dissemund J. Wound debridement with a new debrider: A case report series about dermatological patients with chronic painful ulcerations of differing aetiology. EWMA conference, Vienna, Austria 2012
- Girip L, McLoughlin A. Safe debridement at home – a case study. Wounds UK conference, Harrogate, UK 2013
- Unpublished data on file
- Unpublished data on file
- Wounds UK. The all Wales guidance for the management of hyperkeratosis of the lower limb. Wounds UK, London 2014
- Wounds UK. Management of hyperkeratosis of the lower limb: Consensus recommendations. London: Wounds UK, 11(4) Supplement 2015
- Whitaker J. Self-management in combating chronic skin disorders. *Journal of Lymphoedema* 2012. 7(1):46-50
- Pidcock L, Jones H. Use of a monofilament fibre debridement pad to treat chronic oedema-related hyperkeratosis. *Wounds UK* 2013. 9(3) 89-92
- Williams A. Chronic oedema in patients with CVI and ulceration of the lower limb. *British Journal of Community Nursing* 2009. 14(10): S4-8
- Johnson S et al. A multi-centre observational study examining the effects of a mechanical debridement system. *Journal of Community Nursing* 2012. 26(6):43-46
- Greaves T. The value of collaborative working with industry in a community setting. Wounds UK conference, Harrogate, UK 2013
- Harding C. The management of a patient with bilateral lymphoedema and papillomatosis. Wounds UK conference, Harrogate, UK 2013
- Whiteside L, McIntyre T. Providing a holistic approach to skin care. BLS conference, Birmingham, UK 2013
- Elwell R. Consensus and action: the impact of the new UK hyperkeratosis Best Practice document in lymphoedema care. Tissue Viability conference, Cardiff, UK 2016
- Freeman N et al. A case study supplement: Real-life perspectives on use of Monofilament Fibre Technology in practice. *Wounds UK* 2016: 12-13
- Foot in Diabetes UK of behalf of College of Podiatry. The Principles of Debridement: The Diabetic Foot. Developing a Scope of Practice for Podiatrists in the UK. SB Communications Group 2014. London, UK
- Young T. The introduction of a novel skin care regimen in an elderly inpatient population. EWMA conference. London UK, 2015
- Bower C. Actinic Keratosis – Guidelines and management. *Dermatological Nursing* 2015. 14(2):(suppl) s4-s8
- Heron A. The impact of a monofilament debridement pad in the management of Actinic Keratosis. Wounds UK conference. Harrogate, UK 2014
- Unpublished data on file
- Lorenzelli D. The management of skin conditions with monofilament fibre technology. Wounds UK conference. Harrogate, UK 2015
- Finlay AY, Khan GK. Dermatology Life Quality Index (DLQI): A simple practical measure for routine clinical use. *Clinical and Experimental Dermatology* 1994. 19: 210–216
- Edwards J. Novel uses for a Monofilament Fibre Debridement pad. Wounds UK conference. Harrogate, UK 2015
- Barea A. Safety and efficacy of a monofilament fibre pad for superficial debridement prior to photodynamic therapy: a review of 20 cases. BDNG conference. Bournemouth, UK 2016
- Wiegand C et al. Evaluation of the cleaning capacity of a monofilament debrider device compared to conventional cosmetic pads in a sebum model. Wounds UK conference. Harrogate, UK 2017
- Eberlein T et al. First experiences in use of a monofilament fibre pad in the treatment of patients suffering from retentive and cystic manifestation of acne. Wounds UK conference. Harrogate, UK 2017.

This article is a promotional item commissioned by L&R UK Limited.



### Debrisoft®



For shallow wounds and accessible areas of skin

### Debrisoft® Lolly



For hard-to-reach areas e.g. cavity wounds, between digits and skin folds

# The Debrisoft® Difference

For effective wound bed and skin preparation, nothing else works like Debrisoft®.

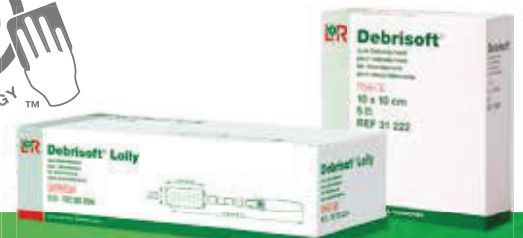Its unique, patented Monofilament Fibre Technology™ **lifts** up and **binds** superficial slough and debris, including biofilm, quickly and easily, **removing** barriers to healing.

Debrisoft® pad is recommended by  NICE.



People.Health.Care.

**97%** of clinicians would recommend Debrisoft®\*



DEBRISOFTING™  
EFFECTIVE DEBRIDEMENT. HEALTHY TISSUE.

TO LEARN MORE ABOUT OUR CLINICAL EVIDENCE RELATING TO SKIN CONDITIONS, PLEASE CALL 08450 606707

OR REQUEST A SAMPLE AT [WWW.DEBRISOFT.CO.UK/SAMPLES](http://WWW.DEBRISOFT.CO.UK/SAMPLES)

\* Data from The Debrisoft® Difference Challenge (on file) ADV288 V2.2