

OBSERVATIONAL, INTERNATIONAL, MULTICENTRE, SINGLE-ARM STUDY TO ASSESS THE PERFORMANCE, SAFETY AND HANDLING OF NEW ANTIMICROBIAL HYDRO-ACTIVE FIBRE DRESSING*

**Erol Mete¹, Gabriele Westermann²,
Claudia Rainer³, Claas Roes⁴**

¹ St. Vinzenz Hospital, Dr.-Otto-Seidel-Straße 31-33, 46535 Dinslaken, Germany;

² St. Johannes Hospital Dortmund, Johannesstraße 9-17, 44137 Dortmund, Germany;

³ Ordination Dr. Razek Peter, Donaufelderstraße 198, 1220 Wien, Austria;

⁴ Lohmann & Rauscher GmbH & Co. KG, Westerwaldstraße 4, 56579 Rengsdorf, Germany



For more information
on the product being tested,
visit the L&R publication database.

EWMA 2024 • EP091 • May 01st-03rd
London, UK

Scientific grand by Lohmann & Rauscher GmbH & Co. KG
*Suprasorb[®] Liquacel Ag – Speciality Fibres and Materials Ltd

Aim

Infected or infection-prone wounds are a challenge in wound care, requiring effective infection management and wound exudate control [1]. A new antimicrobial hydro-active fibre dressing* containing silver nanoparticles was developed for these needs. This study aimed to assess the product's performance, safety, and usability in managing such wounds.

Method

The **observational study** took place at **6 centres** in Germany (n=5) and Austria (n=1). Eight wound managers treated **81 patients** (46% male/54% female) with the investigated product, performing at least **4 dressing changes over 7 to 28 days** as per instructions. Results were collected via an electronic questionnaire. Patients' average age was **66.88 ± 16.17 years**. The study adhered to the declaration of Helsinki and complied with §3 clause 4 of the German Medical Devices Act (MPDG) and §47 Section 3 of the MPDG.



*Suprasorb® Liguacel Ag – Speciality Fibres and Materials Ltd

References

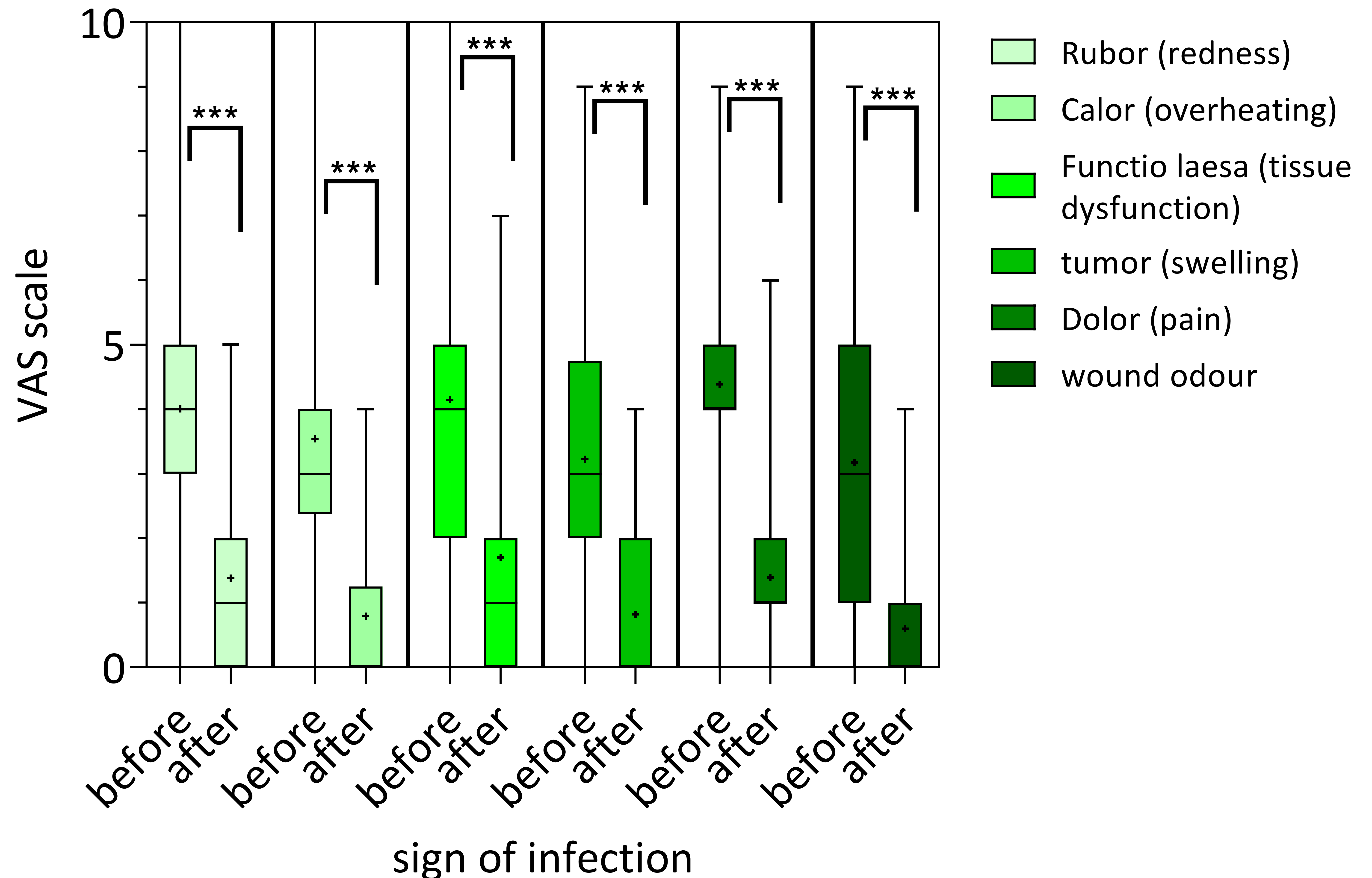
- [1] International Wound Infection Institute (2022) 'Wound Infection In Clinical Practice: Principles of best practice', Wounds International.

Results I

The study included patients with various medical conditions, such as venous leg ulcers (24.69%), postoperative wounds (13.35%), second-degree burns (12.35%), pressure injuries (12.35%), diabetic ulcers (12.35%), traumatic wounds (12.35%), and wounds prone to bleeding (12.35%). Among these wounds, 41% were deep, and 59% were superficial. Regarding exudation, 75% had a moderate level, while 25% had a high level. Over the study period, signs of infection such as redness, overheating, tissue dysfunction, swelling, pain, and wound odour were significantly reduced by an average of 2.64 on the Visual Analog Scale (VAS) [Graph 1].

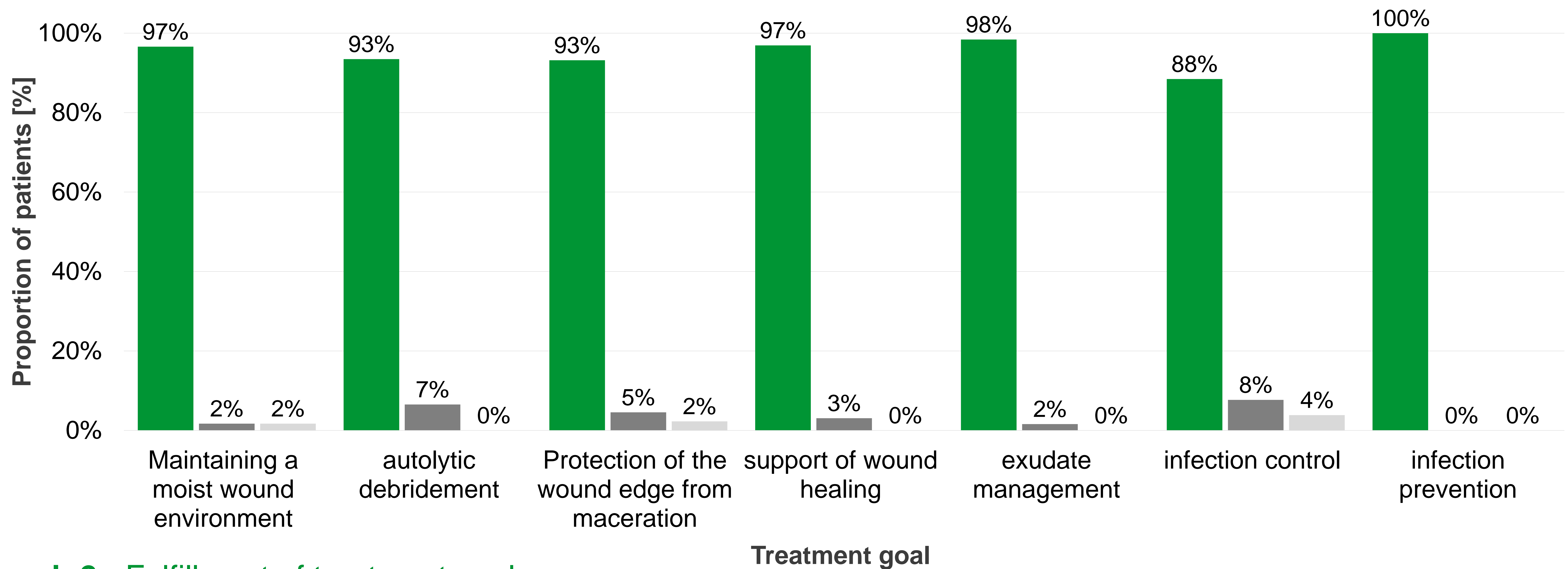
Graph 1: Reduction of infection signs

Box-and-whisker plot illustrating the reduction in infection signs throughout the study period. The values before the start of the study (pre) and after the completion of the study (post) are presented. Mean values are denoted by '+'. The whiskers on the graph represent the highest and lowest values reported on the Visual Analog Scale (VAS). The observed reductions are statistically significant ($p > 0.001$).



Results II

On average, practitioners successfully achieved their treatment goals, including maintaining wound moisture, facilitating autolytic debridement, protecting the wound edge from maceration, supporting wound healing, managing exudate, controlling existing infections, and preventing new infections. These goals were achieved at a rate of 95.3% using the investigated wound dressing [Graph 2]. In 100% of the wounds, the gelled wound dressing effectively removed cellular debris from the wound. The dressing conformed to the wound in 98.8% of cases. Only 3.7% of the wounds experienced gelation extending beyond the wound's edge, and wound exudate spread beyond the wound edge in only 26% of cases.

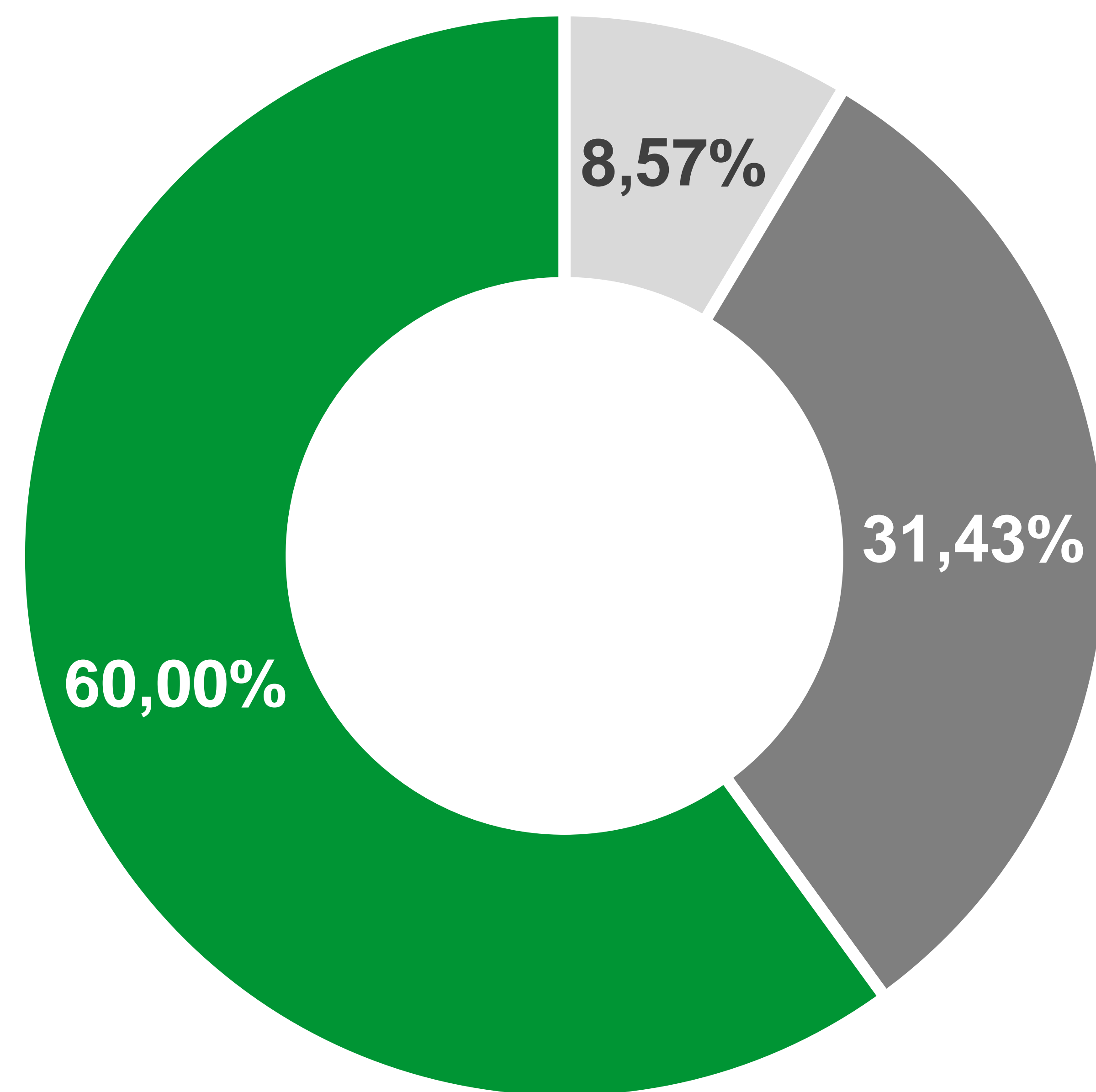


Graph 2: Fulfillment of treatment goals

Proportion of patients for whom the treatment goals, as set by the user, were fully achieved (■), partially achieved (■) and not achieved (■) using the hydro-active fibre dressing.

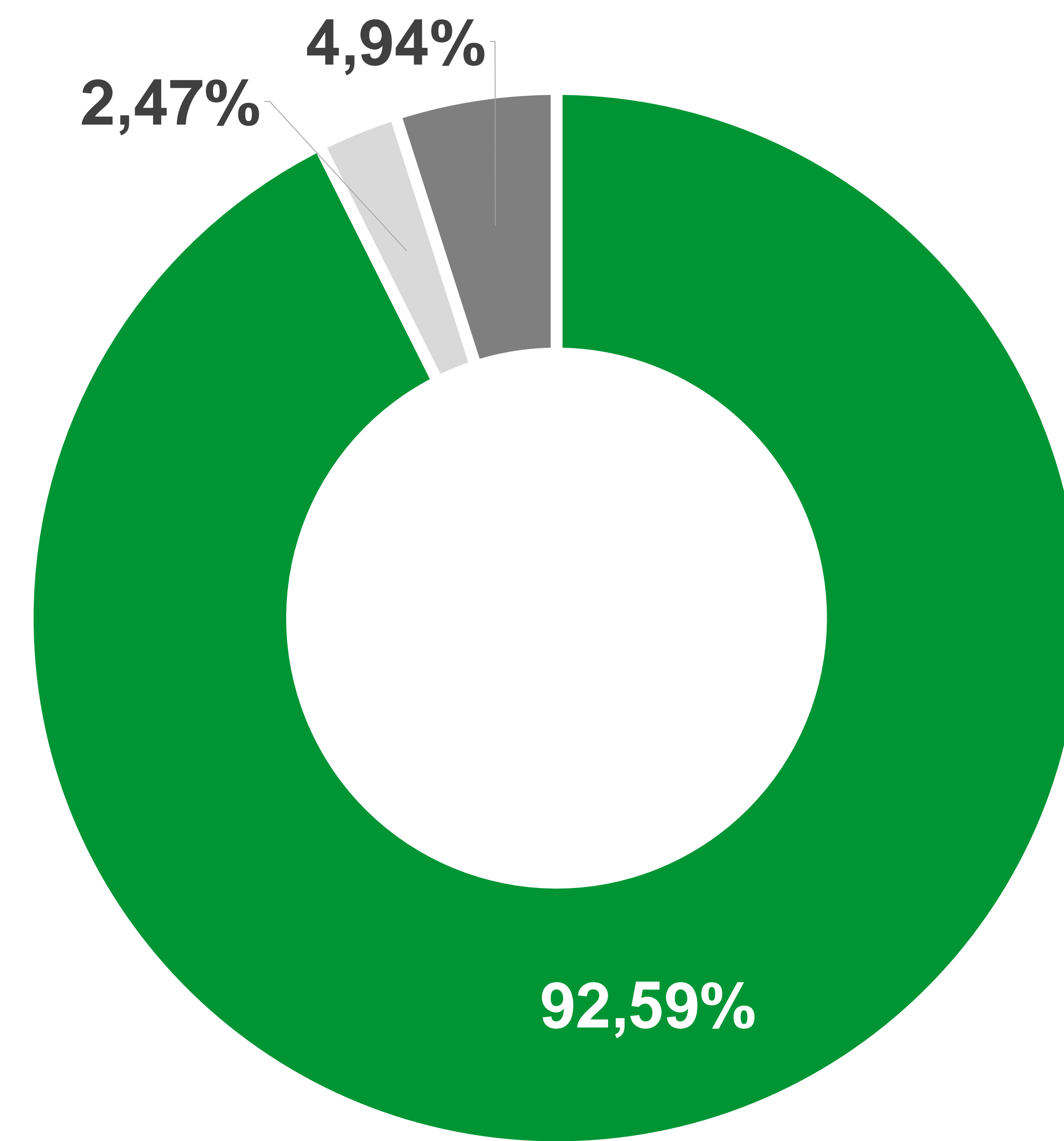
Results III

Biofilm was no longer visible in 60% of the treated wounds that initially showed visible biofilm at the beginning of the treatment. In 31% of cases, biofilm was still partially visible [Graph 3A]. Maceration was caused by the dressing in only 2.5% of cases [Graph 3B]. In all cases, wound exudate was successfully directed into the secondary dressing. The dressing could be removed intact in every case. In 12.4% of cases, easily removable fibre residues remained in the wound. The dressing adhered to the wound bed in 5% of cases. Dressing changes were atraumatic in all cases, and the dressing could be cut to fit the wound in every instance.



Graph 3A: Reduction of visible biofilm

Proportion of patients exhibiting the absence (■), partial presence (■) and presence (■) of visible biofilm at the conclusion of the study period.



Graph 3B: Prevention of maceration

Proportion of patients without maceration (■), with maceration caused by the secondary dressing (■) and attributed to the hydro-active fibre dressing (■) during the study period.

Conclusion

The study showed the new wound dressing is effective for managing infected or infection-prone wounds.