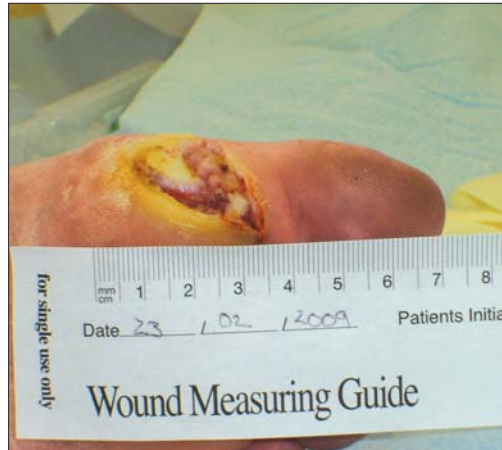
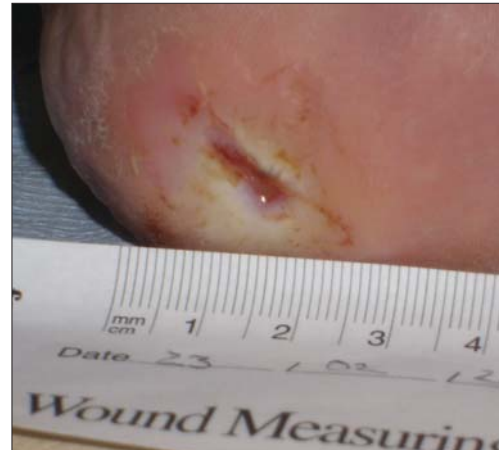
The role of the Tissue Viability Nurse in the management of diabetic foot ulceration

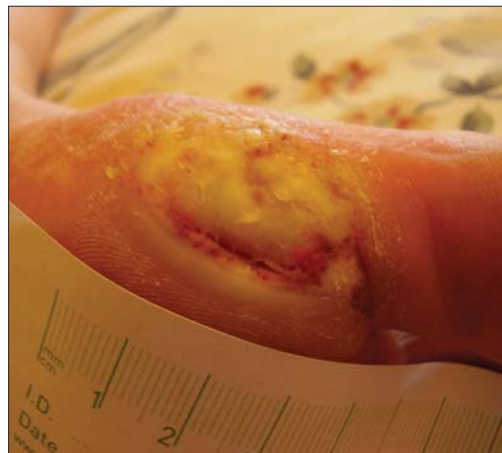Pamela Scott, Tissue Viability Nurse, NHS Cumbria, Wigton Hospital, Cumbria.



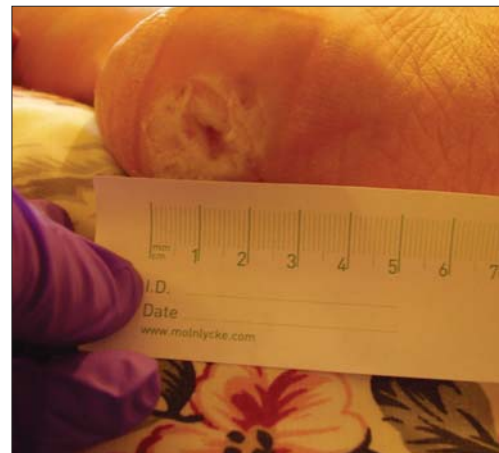1. Metatarsal ulcer on presentation



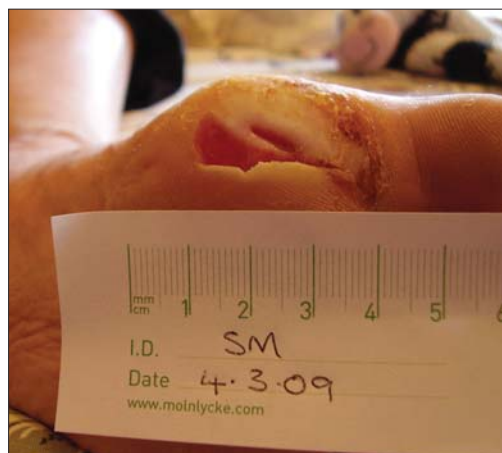2. Heel wound on presentation



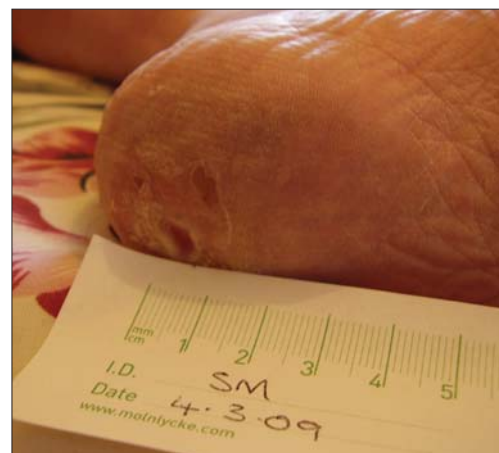3. Metatarsal wound after 4 days



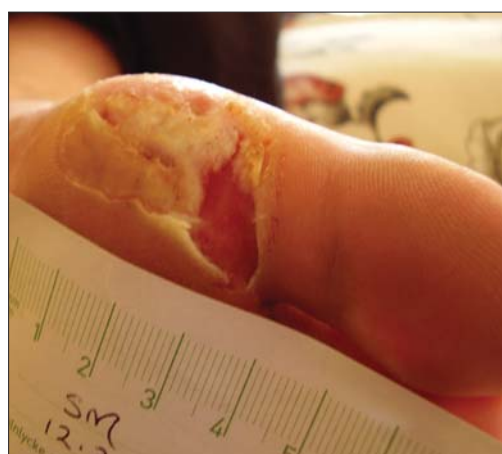4. Heel wound after 4 days



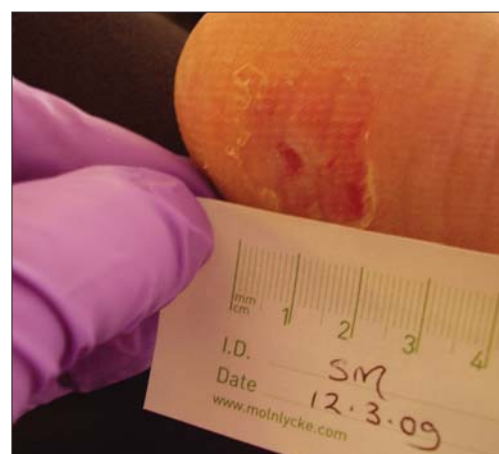
5. Metatarsal wound at 9 days



6. Heel wound at 9 days



7. Metatarsal epithelialising at 19 days



8. Heel ulcer at 19 days

Introduction

The treatment of diabetic foot ulceration can be highly complex and challenging, which often requires a number of specialist skills from a number of specialised areas of care. The benefits of multidisciplinary working in diabetic foot care are well established (Edmonds et al 1986). In this case study the author will demonstrate the role of the tissue viability nurse in the treatment of a poorly controlled diabetic patient with foot ulceration.

Mrs B was a 49 year old unstable, insulin dependent diabetic with both osteomyelitis to a left heel ulcer and an ulcerated left metatarsal. Her underlying conditions increased her risk of compromised healing. The origin of Mrs B's ulceration was a combination of her poorly controlled diabetes and her reluctance to change from wearing high heeled shoes. Due to the nature of the osteomyelitis and underlying condition, the possibility of potential amputation had also been broached.

Mrs B had previously been seen by a number of multidisciplinary specialists including her GP, the vascular team, podiatry, orthopaedic outpatients and the tissue viability nurse. She would also change her dressings herself between appointments and historically there had been episodes of non-compliance and wound interference.

Method

A large proportion of patients with diabetic foot ulceration will develop infection including osteomyelitis and gangrene (O'Meara et al 2008). Due to the infection in her heel and the risk of infection to her metatarsal; both wounds were treated with the same regime. Previous treatments had included foam dressings, silicone dressings, honey, and an antimicrobial alginate gel.

Mrs B had been taking long term Flucloxacilin. However, when she was diagnosed with osteomyelitis in her heel via an isotope scan and X-rays, these were changed to Clarythromycin. It was also at this point that the tissue viability nurse became involved in Mrs B's care.

When Mrs B presented to the tissue viability nurse her heel ulcer measured 1cm x 0.3cm and her dermal metatarsal head wound measured 3cm x 2cm with thick callus formation around the metatarsal. She gave a visual analogue scale (VAS) for pain of 6/10. Wound swabs identified profuse Staphylococcus aureus and Streptococcus Group G. Both wounds had 100% granulation; however they were static in their progress.

Mrs B stated that she wanted a dressing that would stay on and would be comfortable. Both wounds were treated with Suprasorb® X+PHMB (Polyhexamethylene biguanide) and an adhesive foam was used as a secondary dressing.

Suprasorb® X+PHMB is a biosynthetic HydroBalance fibre dressing incorporated with PHMB, a synthetic compound which is structurally similar to naturally occurring antimicrobial peptides (AMP's).

Between clinic appointments Mrs B changed her dressing every two days. During this time she attempted to debride the callus formation herself.

Results

Due to its ability to absorb and donate moisture, Suprasorb® X+PHMB had a cooling effect on the wound. Within four days Mrs B noted a reduction in her wound pain from 6/10 to 3/10.

Also, due to the antimicrobial properties from within the dressing and also on the wound dressing interface, Mrs B's wounds significantly improved within two weeks and completely healed within four weeks.

Discussion

The improvement to her wound pain and wound condition resulted in Mrs B becoming more compliant with her treatment and she, in turn, developed a level of trust with the tissue viability nurse.

Conclusion

Diabetic foot ulcer care requires a multidisciplinary approach. However, patient compliance and ownership is an area that has to be addressed to gain the optimum achievement.

In this case study Suprasorb® X+PHMB proved to be a significantly effective treatment for this patient.

References

Edmonds M.E, Blundell M.P, & Morris M.E (1986) Improved survival of the diabetic foot. The role of the specialist foot clinic. QJ.Med 60 (232): 763-771

O'Meara S, Al-Kurdi D, Ovington L,G (2008) Antibiotics and antiseptics for venous leg ulcers. Cochrane Database of Systematic reviews. Issue 1, Art No: CD003557, D01:10.1002/14651858. CD003557. Pub 2.