Use of a Novel Device for Selective Mechanical Debridement of Chronic Wounds

Carolyn Cuttino, RN, BSN, CWCN, CWS; Charleston, South Carolina
Dot Weir, RN, CWON, CWS; Orlando, Florida

SAWC Spring, Atlanta, USA, 2016

Introduction

Wound debridement is well accepted as an essential component of wound bed preparation and has been shown to be essential in achieving wound closure[1,2]. Wound debridement can be accomplished by one or more of several options: sharp/surgical, mechanical, enzymatic, autolytic, and biosurgical.

There is no singular approach that can be used for all patient and wound types. Consideration must be based on a careful assessment of the patient, goals of care, characteristics of the wound, clinical setting, skill level of the clinician, and availability of resources.

We are presenting our experience with a novel new monofilament fiber technology* which provides immediate visual results, removing superficial debris while sparing newly formed granulation tissue. We have found it to be remarkably painless in the patient use to date, providing for exceptional patient acceptance. The technology also has application in the removal / exfoliation of dry hyperkeratotic skin in the peri-wound and on the lower extremities of patients with venous insufficiency and lymphedema.

This collection of before and after photographs utilizing this new technology illustrates our early experience in different sites of service on different wound and skin types. It is evident that once trained, clinicians in virtually all care settings can use the technology as an adjunct to all types of debridement or as a stand-alone modality.

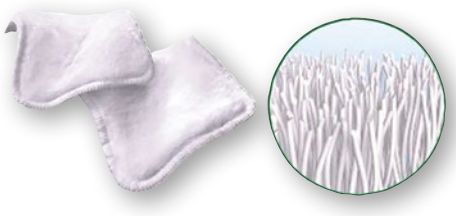

What is it and how does it work?

It is a 10 x 10 cm pad made of monofilament polyester fibers with a reverse side of polyacrylate. The monofilament fibers are cut with angled tips designed to penetrate irregularly shaped areas and remove devitalized skin and wound debris. The device is thoroughly moistened with solution of choice, and the wound or skin is cleansed using repetitive circular motions with gentle, tolerable pressure for 2-4 minutes.

Wound Bed

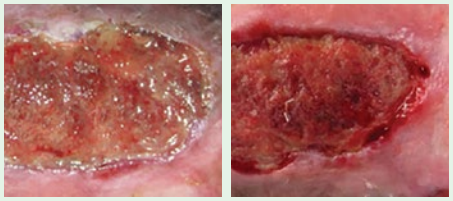

Wound Clinic: Venous ulcer from previous case. 2-3 minute scrub with device removed loose debris.

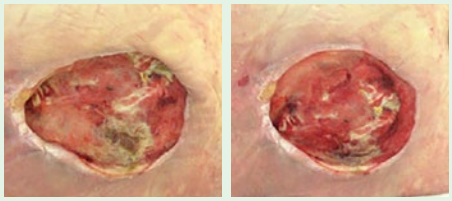

LTC Resident: Stage IV sacral pressure ulcer with bone exposed, being vtreated with collagenase. Device wet with Dakin's quarter strength (0.125%) used by nurse for 2 minutes removing significant amount of loose slough.

Wound Clinic: Neuropathic ulcer on lateral foot, device used for less than 1 minute. Further sharp debridement of wound edge required.

LTC Resident: Plantar foot ulcer covered with dry, adherent coagulum leading nurses to the assumption that the wound was "healed". Device used for 2 minutes to reveal wound bed facilitating accurate wound assessment.

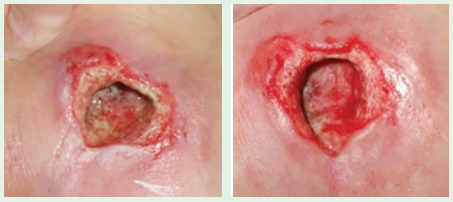

LTC Resident: Very painful wound being treated daily with Collagenase; device used for 2 minutes with no complaints of pain. Collagenase was able to be discontinued the following week.

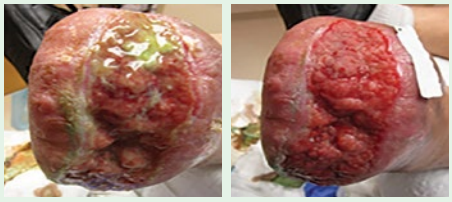

Wound Clinic: Trans-metatarsal amputation showing exudates and necrotic tissue after removal of dressing and after 3-4 minute scrub with device.

Wound Clinic: Patient with venous insufficiency ulcer and dermatitis, with residue and hyperkeratotic scales in periwound area. Device used with tap water to cleanse and de-scale periwound area before addressing the wound.

Periwound and Hyperkeratotic Skin

Acute Care: Bed bound incontinent patient with remnants of zinc based barrier ointment and fragile skin. Skin cleansed gently with device wet with tap water for less than 1 minute.

Wound Clinic: Patient with mixed venous insufficiency and lymphedema with classic appearance of brawny fibrotic skin mixed with papillomatosis. 3 pads saturated with tap water used over 15 minutes.

Wound Clinic: Dry flaky skin which normally moisturizers would yield only temporary results. Device used for just a few minutes with more effective exfoliation allowing better penetration of emollients or topical medications.

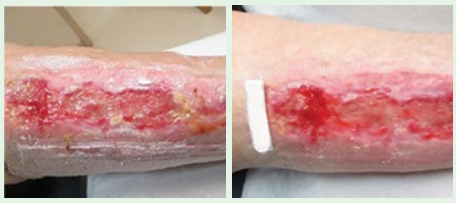

Wound Clinic: Post radiation injury with exquisitely painful wound and fragile periwound skin. Device used for 1-2 minutes with minimal pressure.

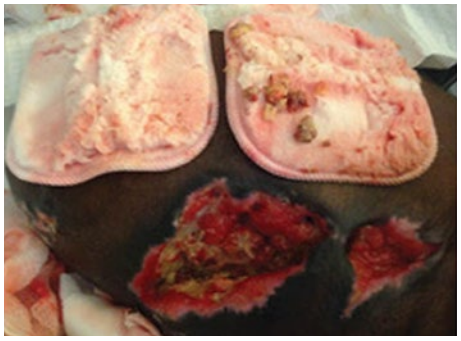

Cellular debris, loose slough, exudate and hyperkeratotic tissue become integrated into the monofilaments and are removed from the wound site. A new device is normally needed for each separate wound being treated. For large areas, more than 1 may be needed.

Implications for Practice

- Faster / effective wound bed preparation in the hands of the bedside nurse
  - Cost savings in time
- Virtually painless in our experience so far
  - May be used with topical anesthetics if needed
- Ideal adjunct with other forms of debridement
- Able to be used in all sites of service especially when instrument debridement not desired or not an option
- Effective preparation of the site just prior to cellular and tissue-based products.
- Immediate visual changes in the wound bed
- Pressure / force is in the hands of the clinician
  - Found to be less traumatic to the wound bed
  - Less bleeding in management of hypergranulation tissue
- Remarkably effective in removing hyperkeratotic skin and scales, removing previous treatment residues and other unwanted debris in the peri-wound area.
- Patient acceptance has been significant.
  - Effective cleansing of wound bed with minimal to no discomfort improves trust and patient satisfaction
  - Ability to remove scales and dry skin aids in the use of emollients, reduction of itching, improvement of dermatitis
  - Allowing patient to initially use pad on their own wound instills confidence and can reduce anticipatory pain.

As with any new technology, experience will teach us what it will and will not do. When addressing densely adherent necrotic tissue use in conjunction with other debridement modalities (i.e. enzymatic, autolytic) will enhance the effectiveness of both. ■

References

1. Sibbald, RG et al. Special considerations in wound bed preparation 2011: An update. Advances in Skin & wound Care, 24(9), 415-436.
2. Steed DL, Donohoe D, Webster MW, Lindsley L. Effect of extensive debridement and treatment on the healing of diabetic foot ulcers. Diabetic Ulcer Study Group. J Am Coll Surg. 1996;183(1):61–4.
3. http://www.nice.org.uk/guidance/MTG17 Accessed 8/25/15
4. Strohal R, Apelqvist J, Dissemond J et al. EWMA Document: Debridment. J Wound Care, 2013: (Suppl. 1) S1-S52

* Debrisoft® Lohmann & Rauscher, Milwaukee WI